# Vaginal Physical Examination Correlates with Vaginal Epithelial Cells and pH and Can be Used to Assess Treatment Efficacy

Ginger D. Constantine, MD[1]; Harvey Kushner, PhD[2]; Brian Bernick, MD[3]; Shelli Graham, PhD[3]; and Sebastian Mirkin, MD[3]

[1]EndoRheum Consultants LLC, Media, PA; [2]BioMedical Computer Research Institute, Inc; [3]TherapeuticsMD, Boca Raton, FL

## Introduction

- Vulvar and vaginal atrophy (VVA), a common chronic condition of postmenopausal women, is assessed by objective (vaginal cells and vaginal pH) and subjective (symptom severity) measures.
- In clinical practice, healthcare providers (HCPs) often utilize vaginal visual assessments to diagnose VVA with patient reported symptoms to determine appropriate treatment.
- Significant improvements in change from baseline to week 12 must be shown in vaginal superficial cells, parabasal cells, and pH and, improvement in the most bothersome moderate to severe symptom, for a drug to be approved in the U.S. for treating VVA.
- A recent study showed a correlation between visual examinations and objective measures with ospemifene.[1]
- HCP visual assessments as a tool to diagnose VVA and assess response to local vaginal estrogens has not been established.

## Objective

- To examine the relationship between HCP visual assessments on a physical exam of the vagina and objective measures (vaginal cells and vaginal pH), to determine if visual assessments are an appropriate way to establish patient need and responsiveness to VVA treatment.

## Patients and Methods

- Healthy postmenopausal women (aged 40–75 years; BMI ≤34 kg/m$^2$) with ≥1 self-assessed moderate-to-severe VVA symptom, ≤5% superficial cells, vaginal pH >5, and estradiol levels ≤50 pg/mL were randomized to 10 µg of solubilized estradiol in a soft vaginal gelcap (VagiCap™; TX-004 HR; TherapeuticsMD, Inc., Boca Raton, FL) or placebo gelcap for 14 days in this Phase 2 pilot, double-blind trial.[2]
- Efficacy endpoints included change from baseline in the maturation index (percentage of superficial, parabasal, and intermediate vaginal cells), vaginal pH, severity of the most bothersome VVA symptom identified at baseline, and investigator assessment of the vaginal mucosa.
- Four physical visual assessments were evaluated: vaginal secretions, vaginal epithelial integrity, vaginal epithelial thickness, and vaginal color. Each assessment was graded on a 4-point scale, where a severity score of 0 corresponded to characteristics expected to be observed with no atrophy, 1 mild, 2 moderate, and 3 severe (Table 1).
- Visual assessments completed at baseline (day 1) and day 15 were performed by the same gynecologist who was blinded to previous objective assessments and treatment.

**Table 1.** Physician's Visual Assessment of Vaginal Mucosa

| Assessment Criteria | Severity Score | | | |
|---|---|---|---|---|
| | 0 = No atrophy (Normal) | 1 = Mild | 2 = Moderate | 3 = Severe |
| Vaginal secretions | Normal clear secretions on vaginal walls | Superficial coating of secretions, difficulty with speculum insertion | Scant not covering the entire vaginal vault, may need lubrication to prevent pain with speculum insertion | None, inflamed, ulceration noted, need lubrication to prevent pain with speculum insertion |
| Vaginal epithelial integrity | Normal | Vaginal surface bleeds with scraping | Vaginal surface bleeds with light contact | Vaginal surface has petechiae before contact and bleeds with light contact |
| Vaginal epithelial surface thickness | Rugation and elasticity of vault | Poor rugation with some elasticity on vaginal vault | Smooth, some elasticity of vaginal vault | Smooth, no elasticity, constriction of the upper one third of vagina or loss of vaginal tone (cystocele and rectocele) |
| Vaginal color | Pink | Lighter in color | Pale in color | Transparent, either no color or inflamed |

## Statistical Analysis

- Vaginal visual assessments for the vaginal estradiol gelcap (TX-004 HR) and placebo groups were combined to determine whether visual assessments correlated with objective measures (e.g., vaginal cells, pH) at baseline and at day 15.
- The sum of the 4 visual assessment severity ratings (Table 1) was calculated for each woman. Correlations between this visual assessment sum and vaginal cell percentages and vaginal pH at baseline and the change from baseline at day 15 were evaluated by Spearman rho.
- Differences in the shifts from one visual assessment category at baseline to a different category of severity at day 15 were compared between vaginal estradiol and placebo groups using Fisher's exact test.
- A mixed model, repeated measures analysis of variance was used to determine statistically significant differences in means for the 4 visual assessment grades within each cell type or vaginal pH at baseline and at day 15.
- A *P*-value ≤0.05 was considered statistically significant.

## Results

***Subject disposition and baseline characteristics***

- Of the 50 women who were randomized (n=24 vaginal estradiol gelcap; n=26 placebo), 48 completed the study; 2 women in the placebo group discontinued (consent withdrawal [n=1] and adverse events [n=1; paresthesia and vulvovaginal discomfort]).
- Women (n=48) were a mean age of 62.5 ± 6.5 years and had a mean BMI of 26.9 ± 3.7 kg/m$^2$. Mean percentages of superficial, parabasal, and intermediate cells were 0.9 ± 2.0, 63.5 ± 39.1, and 35.5 ± 37.9, respectively, at baseline.

***Correlation of Vaginal Cell Types and pH with the Sum of Visual Assessments***

- At baseline, significant correlations between parabasal and intermediate cell percentages and the sum of the 4 visual assessments were observed, independent of treatment (Table 2). Superficial cells were too few at baseline to observe a significant correlation.
- At day 15, parabasal and intermediate cell percentages and vaginal pH significantly correlated with the sum of the 4 visual assessments when all subjects were analyzed (Table 2 and Figure 1).

**Table 2.** Correlation of Vaginal Cells and pH with the Sum of the Four Visual Assessments*

| Parameter | Correlation Coefficient† | *P*-value |
|---|---|---|
| Baseline | | |
| Superficial (%) | 0.12 | 0.4 |
| Parabasal (%) | 0.29 | 0.05 |
| Intermediate (%) | -0.32 | 0.03 |
| Vaginal pH | 0.07 | 0.7 |
| Change from baseline to day 15 | | |
| Superficial (%) | -0.22 | 0.1 |
| Parabasal (%) | 0.38 | 0.008 |
| Intermediate (%) | -0.36 | 0.01 |
| Vaginal pH | 0.35 | 0.02 |

*The sum of the each visual assessment severity rating (0 = no atrophy, 1 = mild, 2 = moderate, 3 = severe) for each woman (n=48) independent of treatment.

†Spearman rho correlation coefficient.

**Figure 1.** Correlations of Vaginal Cell Changes from Baseline with the Sum of the Four Visual Assessments at Day 15

**A.** Parabasal Cells

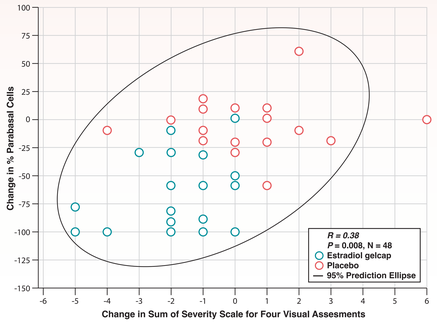


**B.** Intermediate Cells

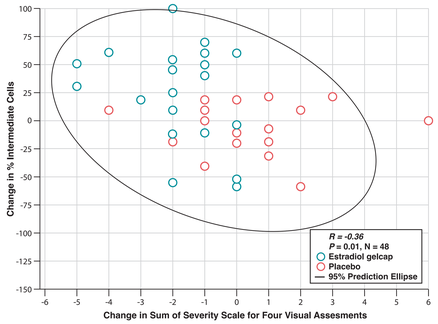


***Shifts in Visual Assessment Categories***

- Significant improvements in severity scores from baseline to day 15 were observed for vaginal epithelial integrity, vaginal secretions, and vaginal color, but not vaginal epithelial thickness, with the vaginal estradiol gelcap versus placebo (Figure 2A-D).
- In general, more shifts from mild or moderate at baseline to no atrophy at day 15, or moderate at baseline to mild at day 15 (improvements) were seen with the vaginal estradiol gelcap than with placebo.

***Vaginal Visual Assessments***

- At baseline, no statistically significant comparisons were observed among severity grades within each cell type for vaginal secretions, epithelial integrity, or epithelial thickness when all women were collectively analyzed. For vaginal color, significant differences were observed with parabasal cells for mild versus no atrophy (*P*=0.03), and parabasal (*P*=0.004) and intermediate cells (*P*=0.02) for moderate vs. no atrophy.

**Figure 2.** Shifts in Visual Assessments from Baseline to Day 15

**A.** Vaginal Epithelial Integrity

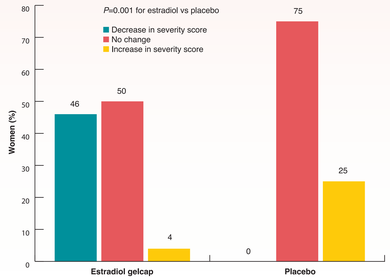


**B.** Vaginal Secretions

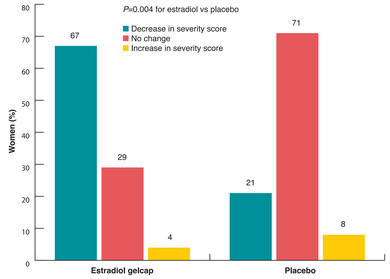


**C.** Vaginal Color

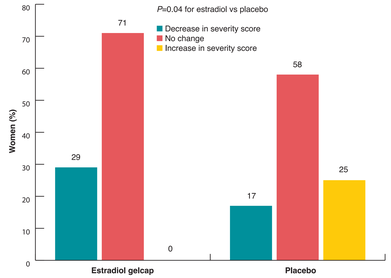


**D.** Vaginal Epithelial Thickness

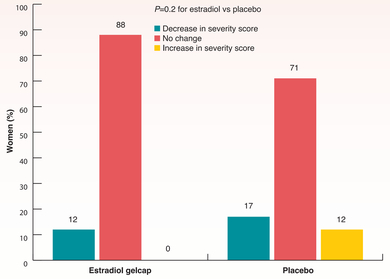


- By day 15, significant differences in percentages of superficial cells were observed between mild versus no atrophy for vaginal secretions (*P*=0.05).
- Percentages of parabasal cells at day 15 were significantly different between mild versus no atrophy for vaginal secretions (*P*=0.03) and epithelial integrity (*P*=0.0006), and between moderate versus mild for vaginal epithelial thickness (*P*=0.03).

***Vaginal pH***

- At baseline, for all women, vaginal pH was significantly different for mild versus no atrophy for vaginal secretions (*P*=0.04) and moderate versus mild atrophy for vaginal color (*P*=0.03).
- At day 15, vaginal pH was significantly different for mild versus no atrophy for vaginal epithelial integrity (*P*<0.0001) and moderate versus no atrophy for vaginal color, regardless of treatment (*P*=0.05).

## Conclusions

- A new gelcap of 10 µg solubilized estradiol significantly improved vaginal epithelial integrity, vaginal secretions, and vaginal color relative to placebo. This is consistent with the first report of this pilot study showing significant improvements in vaginal maturation index, pH, and epithelial integrity, and vaginal secretions.[2]
- Visual assessments of vaginal atrophy correlated with objective measures, including parabasal and intermediate cells at baseline and at day 15, and vaginal pH at day 15.
- This vaginal estradiol gelcap (4, 10 and 25 µg) is being studied in a phase 3 trial.
- Visual assessments of the vagina by HCPs are shown here to be valid and reliable measures to diagnose VVA and assess response to treatment.

## References

1. Constantine GD, Graham S. Ospemifene improves objective measures of vulvar and vaginal atrophy (VVA). Menopause 2013;20:12(1335).
2. Pickar JH et al. Pilot and pharmacokinetic studies of solubilized estradiol administered vaginally in a softgel capsule. Menopause 2014;21:12(1328).

## Disclosures

TherapeuticsMD funded this study and medical writing assistance provided by Chastity Bradley, PhD and Kathleen Ohleth, PhD (Precise Publications, LLC). Dr. Constantine consults for pharmaceutical companies including but not limited to TherapeuticsMD. Dr. Kushner is a statistical consultant. Drs. Bernick, Graham and Mirkin are employees of TherapeuticsMD.

*Presented at the Annual Meeting of the Endocrine Society, March 5-8, 2015, San Diego, CA*